Indian Journal of Pathology: Research and Practice 8(2) March-April 2019
DOI: http://dx.doi.org/10.21088/ijprp.2278.148X.8219.13

IJPRP

Original Research Article

Insights of Uterine Leiomyomas

Ramesh B.H.[1], Rajeshwari K.[2]

[1]Professor & Head, Department of Pathology, Raichur Institute of Medical Sciences, Raichur, Karnataka 584102, India. [2]Assistant Professor, Department of Pathology, Gulbarga Institute of Medical Sciences, Gulbarga, Karnataka 585101, India.

Abstract

Background: Fibroid is the commonest tumor of the reproductive tract and frequently encountered problem in gynecological practice.

Aim and objectives: To observe the frequency of uterine leiomyoma in relation to age, parity, clinical manifestations, morphology, secondary changes, endometrial status and associated pelvic pathology.

Material & methods: Over a period of two years, 1866 hysterectomy specimen sent for histopathology was studied. Uteri with fibroids were included for the study. Clinical data including age, parity, menstrual pattern, presenting symptoms, surgical treatment history of these patients with fibroid was collected and analyzed.

Results: Leiomyoma was diagnosed in 350 patients out of 1866 hysterectomies (19.12%). Greater frequency (83.42%) was found in late reproductive and perimenopausal years ie 4th and 5th decade with a mean age of 40.9 years. Most of the patients were multiparous (98.09%). Menorrhagia (46.17%) was the commonest symptom followed by dysmenorrhoea (22%). Most of the leiomyomas were intramural type (55.09%). Degenerative changes were observed in 39.41% of leiomyomas and leiomyomas variants in 2.6% of cases.

Conclusion: Leiomyoma is the most common benign tumor of uterus occurring during reproductive age group. Histopathology remains the gold standard method in diagnosing the leiomyoma variants. Accurate histopathological examination is mandatory to rule out malignancy for optimal management and patient well being.

Keywords: Leiomyoma Variants, Hysterectomy; Histomorphology; Degenerative Changes.

Corresponding Author:
Rajeshwari K, Assistant Professor, Department of Pathology, Gulbarga Institute of Medical Sciences, Gulbarga, Karnataka 585101, India.

E-mail: ujwalgk@gmail.com

Received on 17.01.2019,

Accepted on 07.03.2019

How to cite this article:

Ramesh B.H. & Rajeshwari K. Insights of Uterine Leiomyomas. Indian J Pathol Res Pract. 2019;8(2):205-211.

Introduction

Uterine leiomyoma (also referred to as myoma, fibromyoma, or fibroid), is the most common benign neoplasm of the women of reproductive age group constituting 5-20% of the cases. The possible etiology for occurrence of leiomyoma are due to complex interaction of sex steroid harmones and local growth harmones along with mutation in myometrium. Leiomyoma needs harmones and growth factors for its growth and maintatinance and is evidenced by molecular studies and exhibits estrogen and progesterone receptors [1].

Though uterine leiomyomas are common, it is difficult to obtain extensive literature on clinical and pathological aspects of leiomyoma in Indian literature [2]. This prompted the present study, aimed to study the leiomyoma in detail with relation to age, parity and clinical manifestations, morphology, secondary changes, its variants, endometrial status and associated pelvic pathology in hysterectomy patients.

Material & Methods

The present study is a descriptive study carried out over a period of two years from May 2016 – May 2018 in the department of Pathology at a tertiary care centre.

Following inclusion and exclusion criteria were adopted in our study –

Inclusion Criteria

1. All the hysterectomy specimens diagnosed clinically and radiologically as uterine fibroid.
2. Specimens include hysterectomy specimens with or without salphingo-oopherectomy and myomectomy specimens.

Exclusion Criteria

1. Patient who underwent hysterectomy with an indication other than uterine fibroid was excluded
2. Poorly preserved specimens

Brief clinical and demographic data of the patients were collected. A detailed gross examination of uterus, cervix with or without adnexa was carried out. Hysterectomy specimens with well circumscribed and on cut section shows raw silk appearance for diagnosis as leiomyoma [3].

Details regarding the number, location, size, and secondary changes were noted. Representative sections from leiomyoma and other abnormal areas were taken. Additional sections from associated adnexal pathology were also taken, processed and paraffin embedded. The blocks were sectioned of size of 3-5 microns thickness and stained with Haematoxylin & Eosin stain for detailed study of histomorphological features that included the degree of cellularity, crowding and overlapping of nuclei, nuclear atypia, mitoses (per 10 HPF), coagulative necrosis, presence of other secondary changes and variations in morphology and growth pattern were recorded.

Statistical Analysis

The collected data was tabulated, analyzed and subjected for statistical analysis using SPSS 19.0. Results are presented as range for quantitative data and number and percentage for qualitative data.

Results

In our study total Gynecological surgical specimen received constituted 2,790 specimens accounting for 26.41% of the total surgical specimens 10,562 specimens received in the department of pathology during the study period.

Of the 2,790 gynecological specimen, hysterectomy specimen were 1,866 accounting for 66.88% of the cases and out of these leiomyoma was diagnosed in 350 specimen accounting for 19.12% of the cases.

Age

In our study the age range of the patients was between 21-70 years and majority of the patients presented in 4th and 5th decade. The mean age was 40.9 yrs. It was also observed that leiomyoma was commonly seen in multiparous women.

Clincal Presentation

Our study showed that menorrhagia (46.28%) was the commonest symptom followed by dymenorrhoea (22%), pain abdomen (12.57%) and mass per abdomen (14%). (Table 1).

Table 1: Clinical Symptom

Symptoms	No.of Cases	Percentage (%)
Menorrhagia	162	46.28
Dysmenorrhoea	77	22
Pain Abdomen	44	12.57

Mass / Abdomen	49	14
Prolapse	31	8.85
White Discharge per vagina	27	7.71
Mass / Vagina	5	1.42
Backache	8	2.28
Bladder Disturbances	5	1.42
Metrorrhagia	23	6.57
Polymenorrhagia	11	3.14
Sterility	6	1.71
Fever	5	1.42
Amenorrhoea	1	0.28

Morphology

Gross

Majority of leiomyomas were located within the uterus in 96.6% of the cases and the rest were seen in the cervix 3.4% of the cases. In our study, among 350 cases of leiomyoma, 308 cases (88%) were grossly bulky, 40 cases (11.42%) were normal in size and only 2 cases (0.58%) were atrophic.

Our study observed that 72.92% cases of leiomyomas were single in location and rest was multiple (27.08%), with an average of 5-6 and a maximum of 10 in number. Grossly mean size of these leiomyomas was 4.8cms. Majority of leiomyomas were intramural (55.09%) in location, followed by subserosal and submucosal in 29.50% and 15.41% respectively.

Histopathologgy

The present study, showed typical leiomyoma in 203cases (58%) followed by degenerative changes in 138 cases (39.4%) and leiomyomas variants in 9 cases (2.6%) which included one five cases of cellular (1.4%), (Fig. 1), three cases of symplastic (0.9%) (Fig. 2) and one case of epithelioid leiomyomas (0.3%). (Table 2)

Table 2: Types of Leiomyoma

Sl. No	Types of Leiomyomas	No. of cases	Percentage %
1.	**Typical Leiomyomas**	203	58%
2.	**Leiomyoma Variants**	9	2.6%
	a. Cellular Leiomyoma	5	1.4%
	b. Symplastic Leiomyoma	3	0.9%
	c. Epithelioid Leiomyoma	1	0.3%
3.	**Leiomyoma with degenerative changes**	138	39.4%
	a. Hyaline change	146	41.71%
	b. Cystic change	13	3.71%
	c. Mucoid change	07	2.00%
	d. Calcification	08	2.28%
	e. Fatty change	03	0.85%
	f. Leiomyoma with Haemorrhage *	03	0.85%
	g. Leiomyoma with infarction	01	0.28%
	h. Leiomyoma with infection	01	0.28%
	i. Myxoid change	03	0.85%
	j. Necrosis	02	0.57%

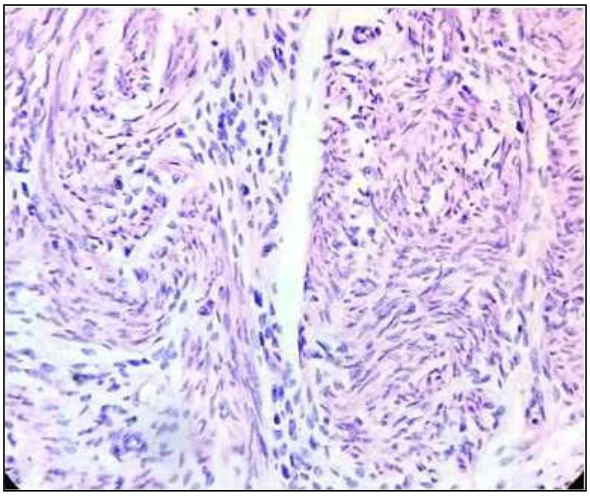

Fig. 1: Microphotograph of cellular leiomyoma with increased cellularity in absence of necrosis, atypia and increased mitosis. (H&E; x400).

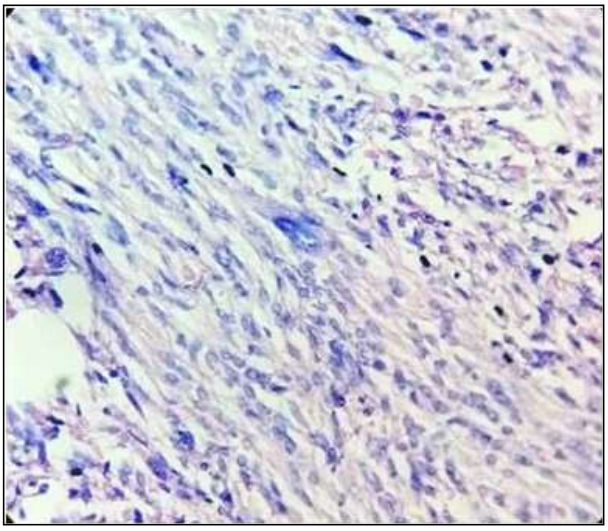

Fig. 2: Microphotograph of Symplastic leiomyoma with bizarre tumour cells in absence of necrosis and increased mitosis (H&E; x400).

Endometrium

In our study of among 350 cases, proliferative phase was found in 169 cases (48.28%), followed by

secretary phase in 106 cases (30.28%), endometrial hyperplasia in 66 cases (18.86%) & atrophic in 9 cases (2.58%). However, there was no specific pathology noted in endometrial stroma in our cases.

Associated Pathology

Our study revealed adenomyosis in 137 cases (39.14%) patients of leiomyomas and hydrosalphnix in 22 cases (6.28%) followed by follicular cyst and serous cystoadenoma were encountered in our study (Table 3).

Table 3: Associated Pathology

Associated pathology	No.of cases	Percentage (%)
Adenomyosis	137	39.14
Hydrosalphinx	22	6.28
Follicular cyst	84	24.00
Simple Serous cyst	02	0.57
Serous cystadenoma	04	1.14
Papillary serous cystadenoma	02	0.57
Carcinoma cervix	04	1.14
Cervical Dyplasia	03	0.85

Discussion

Uterine leiomyomas are the most common benign neoplasms with an incidence of 20-40% in women with reproductive age group [4]. These are monoclonal tumours of uterine smooth muscles and consists of abundant extracellular matrix like collagen, fibronectin, and proteoglycan [4]. Though exact pathogenesis is not clear, there is evidence that eostrogens and progestogens help in proliferating tumour growth [4]. Literature till date has identified various secondary changes and histological variants of leiomyoma. The secondry changes include hyaline change, mucoid, myxomatous change, calcification, cystic changes and fatty metamorphosis.

Histological variants include, cellular leiomyoma, apoplectic leiomyoma, leiomyoma with lymphoid infiltration, atypical (bizarre, symplastic or pleomorphic) leiomyoma, lipoleiomyoma, palisaded leiomyoma, epithelioid (clear cell) leiomyoma, cotyledonoid dissecting leiomyoma, parasitic leiomyoma, leiomyoma with skeletal muscle differentiation, diffuse leiomyomatosis, intravenous leiomyomatosis, benign metastasizing leiomyoma and mitotically active leiomyoma [3].

Leiomyoma in recent days still continue to be a major cause of morbidity in perimenapausal women. Differentiating the usual leiomyoma from leiomyoma variants and its sarcomas in recents days is clinically challenging. Hence, the present study was undertaken to study appropriately the histomorphological features in evaluating the smooth muscle tumours of uterus. Literature search showed that there is limited study on leiomyoma data. Hence, the present study was undertaken to study in detail the secondary changes and the variants of leiomyomas.

In our study; most common benign tumors were leiomyomas with a prevalence of 19.12%. Literature have reported the estimated incidence of 70% of leiomyomas in hystetectomy specimens for benign conditions [5].

In the present study, majority of the leiomyomas were limited to reproductive age group with high prevalence of 49.42% of cases observed between the age groupof 41-50 years and our results are in concordance with the study of Abraham et al., [7] and Mega L et al. studies [8].

In our study, most of the patients were multiparous 91.71% of the cases and 2.6% of the cases were nulliparous and 5.71% of cases were uniparous and is in accordance with the Rosario Pinto [6], Abraham [7] and Mega L study [8].

In the present study most common presenting symptoms was menorrhagia in 46.28% of the cases followed by dysmenorrhoea in 22% of the cases and similar results were noted by Rosario Pinto [6], Abraham [7] and Mega L study [8].

Histomorphological features of Leiomyoma

In our study majority of the leiomyomas were located in the uterus in 96.6% of the cases and the prevalence of cervical leiomyoma was seen in 3.4% of the cases. and our results are in accordance with Rosario P et al. with 4.6% of the cases in their study. The study noted majority of leiomyomas were intramurally located accounting for 55.09% of the cases and our observation is in accordance with Rosario P et al., Mega L et al. Mangala G et al., and Priyadarshini et al studies [6,8,9,10] (Table 4).

The most common secondary change noted in our study is hyaline change in 41.71% of the cases and similar observation was also made by Rosario P et al. [6] Mega L et al. [8] Mangala G et al. [9], and Priyadarshini et al. [10] studies (Table 4).

Endometrial and other associated Pathology

The most common endometrial pathology noted in case of leiomyoma is proliferative phase in 48.28% of the cases and associated Pathology noted in majority of the cases is adenomyosis in 39.14% of

the cases and our results are in concordance with Rosario P et al. [6] Mega L et al. [8] Mangala G et al. [9], and Priyadarshini et al. [10] studies (table 4).

Table 4: Histomorphological features of Leiomyoma in various studies.

Sl.No	Histomorphology	Rosario P 1968 [6]	Mangala G 2013 [9]	Mega L 2016 [8]	Priyadarshini 2018 [10]	Present Study
1.	Intramural Leiomyoma	73.5%	48%	56.86%	67%	55.09%
2.	Hyaline change	8%	16.9%	6.33%	6%	41.71%
3.	Proliferative changes	51.1%	46.3%	-	66%	48.28%
4.	Endometrial stromal changes	-	Absent	-	-	Absent
5.	Adenomyosis	11.3%	-	-	-	39.14%

However there was no significant endometrial stromal changes seen in case of leiomyoma in our study and similar observation was also made by Mangala G [9].

Histological variants of Leiomyoma

The leiomyomas with increased cellularity, mitoses and nuclear atypia poses a diagnostic challenge to the pathologist and should be differentiated from other malignant tumours like Smooth muscle tumour of uncertain malignant potential (STUMP) and leiomyosarcoma.

Smooth muscle tumour of uncertain malignant potential (STUMP) is defined by WHO as smooth muscle tumour that cannot be diagnosed as benign or malignant on the basis of applied criteria [11].

Leiomyosarcoma, a malignant tumour of smooth muscle with increased cellularity, mitoses mor than 10 per 10 high power fields (HPF), diffuse nuclear atypia and coagulative necrosis [3].

In recent days the availability of markers helps in differentiating smooth muscle tumour of uncertain malignant potential (STUMP) and leiomyosarcoma. Leiomyomas express receptor for oestrogen and progesterone whereas leiomyosarcoma show reduced oestrogen and progesterone receptor expression.

In our study variants of leiomyoma seen are cellular leiomyoma, symplastic leiomyoma and epitheiloid leiomyoma.

Cellular leiomyoma defined by WHO as the leiomyoma having cellularity that is significantly greater than the surrounding myometrium [5]. It lacks tumour necrosis, moderate to severe atypia, and have less mitoses [7]. At the genetic level it is accompanied by loss of entire short arm of chromosome 1 [3].

There are other entities of cellular leiomyoma that includes highly cellular leiomyoma and mitotically active leiomyoma. Highly cellular leiomyoma has significant atypia, necrosis or high mitotic activity and as good prognosis than that of usual leiomyoma [7]. Mitotically active leiomyoma refers to the tumour that have 5-15 mitosis/10HPF and lacks necrosis and cytological atypia [7].

Highly cellular leiomyoma mimics typical endometrial stromal tumours that include stromal nodules and low grade endometrial stromal sarcomas and hence need to be differentiated from them. In highly cellular leiomyoma there is fascicular growth pattern of smooth cells and reticulin fibres run parallel to the fascicles of smooth muscle cells of leiomyoma. Immunohistochemistry shows strong positivity to desmin. In case of endometrial stromal tumours reticulin fibres surround individual tumour cells and and network of small blood vessels. Immunohistochemistry shows diffuse positivity to desmin [7].

In our study cellular leiomyoma constituted 1.4% of the cases and is in concordance with Manjula K et al. [12], Abraham et al. [7] and Mega L et al. [8] studies. (Table 5).

Atypical leiomyomas (bizarre, pleomorphic or symplastic leiomyoma) and strongly mimics Leiomyosarcoma. Histopathlogically, atypical leiomyomas consists of bizarre shaped multinucleated and multilobated giant cells with hyperchromatic and pleomorphic with prominent nuclear pseudoinclusions having abundant eosinophilic cytoplasm. The atypical cells have multifocal and patchy distribution. The areas uninvolved show bland cytologic features. The features of atypical leiomyomas that help in differentiating from leiomyosarcoma are low mitotic activity and absence of tumour cell necrosis. The ancillary techniques that help in confirming atypical leiomyomas are ploidy, MIB-1 and p53

expression positivity [7].

In our study atypical leiomyoma constituted 0.9 % of the cases and is in accordance with Manjula K et al. [12] Mega L et al. [8] and Abraham et al. [7], studies (Table 5).

Epithelioid leiomyomas (clear cell leiomyomas) are rare and has potential malignant to get converted into epithelioid leiomyomas with uncertain malignant potential and epithelioid leiomyosarcoma. Epithelioid leiomyomas are small size with well circumscribed margin having extensive hyalinization. Histopathologically, characterized by rounded or polygonal cells with clear cytoplasm. But epithelioid leiomyomas with uncertain malignant potential are larger in size (>6 cm) and histopathologically shows 2-4 mitotic figures/10 HPFswith moderate to severe atypia and necrosis seen. Frank malignant tumours with epithelioid cells are designated as epithelioid leiomyosarcoma [7].

In our study epithelioid leiomyoma constituted 0.3% of the cases and is in consistent with Manjula K et al. [12], Abraham et al. [7] and Mega L et al. [8] studies. (Table 5).

Table 5: Histomorphological variants of Leiomyoma in various studies.

Sl. No	Histolomorphology	Manjula K [12] 2011	Abraham [7] 2013	MegaL [8] 2016	Present study
1.	Leiomyoma variants	4.55%	7.5%	30.38%	2.6%
2.	Cellular	0.22%	5.87%	6.33%	1.4%
3.	symplastic	0.22%	0.36%	1.27%	0.9%
4.	Epithelioid	0.22%	0.1%	-	0.3%
5.	Lipoleiomyoma	2.05%	0.7%	-	-
6.	Myxoid leiomyoma	0.91%		-	-

In recent advances, literature has shown that there are karyotypically abnormal liomyomas that includes cytogenetic abnormalities and seen in 40% of leiomyoma tumours. The cytogenetic abnormalities include (1). translocation between chromosomes 12 and 14, t(12;14) (q14-q15;q23- q24) seen in 20% of karyotypically abnormal leiomyomas. (2). deletion of chromosome 7, del (7) (q22q32), which is present in about 17% of karyotypically abnormal leiomyomas. (3.) Aberrations of 6p21, that includes deletions, inversions, translocations, and insertions. (4.) Trisomy 12 has also been reported in 12% of karyotypically abnormal leiomyomas [13]. (5.) Dysregulation of high-mobility proteins HMGA1 and HMGA2 lead to development of leiomyomas [3].

Conclusion

The present study highlights the importance of through sampling for accurate diagnosis of associated pathology in routine hysterectomy specimens. Histopathology remains the gold standard method in diagnosing the leiomyoma variants. Due to morphological homogeneity of leiomyoma variants, accurate histopathological examination is mandatory and adherence to the diagnostic criteria are required to rule out malignancy for optimal management and patient well being.

References

1. K Geethamala, V srinivas M, B. K. Ramalingiah V, sudha R. Uterine Leiomyoma: An Engima. Journal of Mid- life health 2016; 7:22-7.
2. Novak RE, Jones GS, and Jones HW. Novaks Text Book of Gynaecology. 7th Indian Ed. Scientific Book Agency. Calcutta. 1966: 319-354.
3. Rosai J. Female reproductive system. In: Ackerman's Surgical Pathology. 7th ed. St. Louis: C.V. Mosby Company: 1989.pp.997-1191.
4. Aamir TK, Manjeet S, Janesh KG. Uterine fibroid: Current perspectives. International journal of women's health. 2014:6;95-114.
5. Nucci MR, Oliva E, eds. In: Gynecologic Pathology. A Volume in the Series Foundations in Diagnostic Pathology.Elsevier Churchill Livingstone: 2009.pp. 261-89.
6. Rosario Pinto Y. Uterine fibromyomas. J. of Obstet. & Gynaecol. of India. 1968;18: 101-107.
7. Abraham J, Saldanha P. Morphological variants and secondary changes in uterine leiomyoma. Is it important to recognize them?. International Journal of biomedical research. 2013;4(12):254-64.
8. Mega L, Aneeta S M, Sakul, Arvind K, KC Goswami. Clinicopathological study of uterine leiomyomas in a state of northern india: a hospital based study.

International Journal of reproductive contraception, obstetrics and Gynecology. 2016;5(7):2295-99.

9. Mangala G, Geetha M, Srinivasa M, Vedavathy N. Clinicopathological study of uterine leiomyomas in hysterectomy specimens. Journal of evolution of medical and dental sciences. 2013;2(46):9002-9008.

10. Ph. Priyadarshini and Gomathy. Clinicopathological study of uterine leiomyomas in hysterectomy specimens; a retroseptive study. International. Journal of Advanced . Research. 2018 6(2):571-576.

11. Tavassoli FA, Deville P, eds. In: World Health Organization of Tumours. Pathology and Genetics of Tumours of the Breast and Female Genital Organs. Lyon: IARC Press: 2003.pp.236–42.

12. Manjula K, Kadam SR, Chandrasekhar HR. Variants of Leiomyoma: Histomorphological Study of Tumors of Myometrium. JSAFOG.2011;3:89-92.

13. Flake GP, Anderson J, Dixon D. Etiology and pathogenesis of uterine leiomyomas: a review. Environ Health Perspect. 2003;111:1037-54.